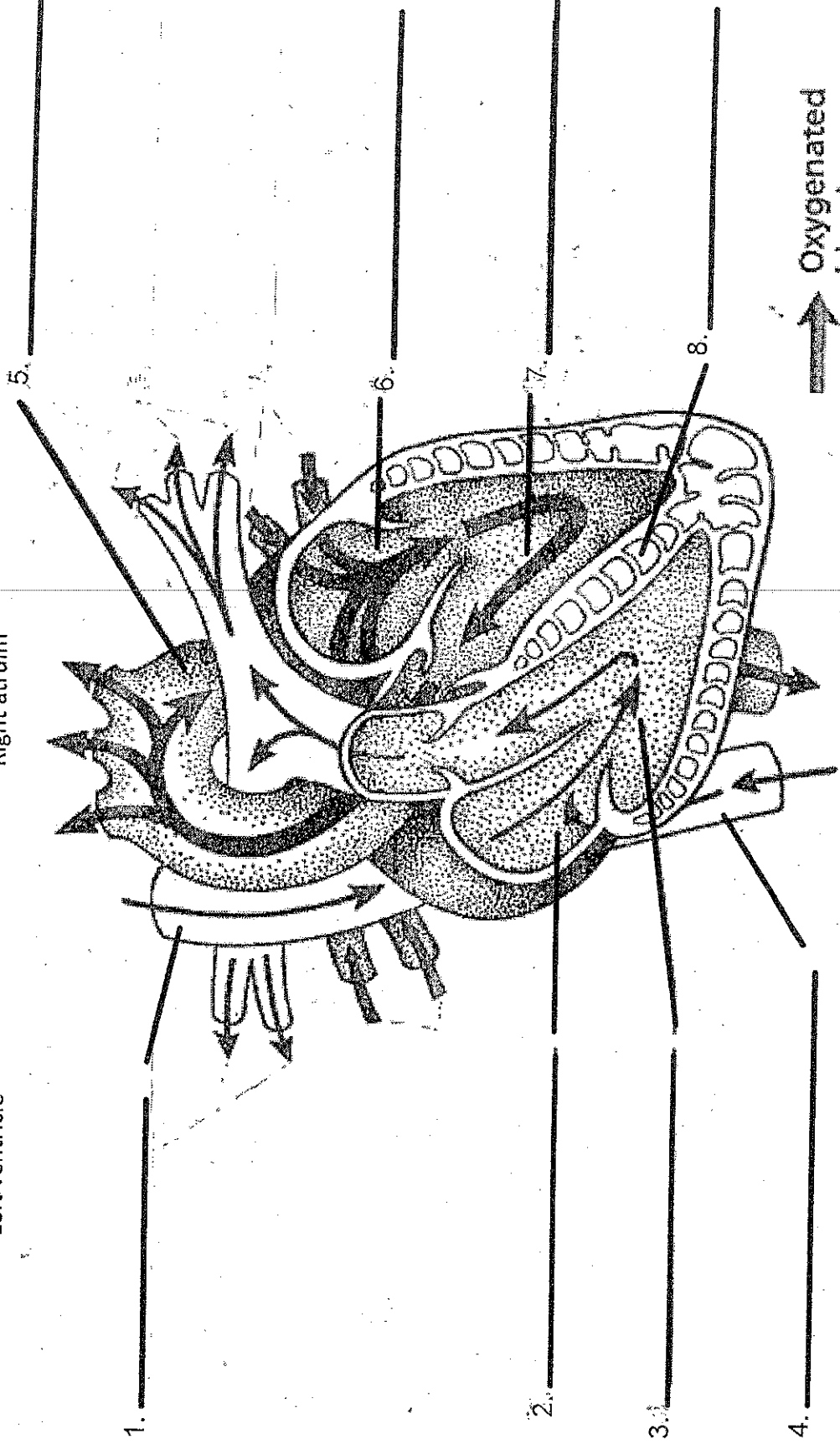


Right ventricle  
Inferior vena cava  
Septum  
Left ventricle

Aorta  
Left atrium  
Superior vena cava  
Right atrium



Oxygenated blood  
Deoxygenated blood